

Case Report

A RARE CASE OF HYDRANENCEPHALY

Zafar sultana ^{*1}, Anantha kumari ², Habib G Pathan ³.

^{*1} Associate Professor of Anatomy, Deccan College Of Medical Sciences, Hyderabad, Telangana, India.

² Professor and HOD of Anatomy, DCMS, Hyderabad, Telangana, India.


³ Professor of Pediatrics and Pediatric Neurologist, DCMS, Hyderabad, Telangana, India.

ABSTRACT

Hydranencephaly is a rare congenital abnormality characterized by replacement of the cerebral hemispheres by a large cerebrospinal fluid pool. It is thought to be caused by occlusion of bilateral internal carotid arteries in the fetal life mainly during the second trimester due to a variety of causes. It is one of the recognized forms of brain malformations which is usually associated with intrauterine fetal demise and is therefore rarely seen in postnatal life. It is a rare entity with a reported incidence of less than 1 per 10,000 live births. Hydranencephaly is an isolated abnormality with a severe prognosis, affecting the cerebral mantle. Midbrain is usually not involved. Differential diagnosis is mainly relevant when considering severe hydrocephalus, porencephalic cyst and alobar holoprosencephaly. Clinical features include intact brainstem reflexes without evidence of higher cortical activity. Infants with this condition are normal at birth however, after a few weeks, they usually become irritable and have increased muscle tone and, after a few months of life, seizures and hydrocephalus (excessive accumulation of CSF in the brain) may develop. Other symptoms are growth retardation, impaired vision, deafness and spastic paralysis. Due to the late onset of most symptoms and signs, the diagnosis may be delayed.

KEY WORDS: Hydranencephaly, Internal carotid artery occlusion, cerebrospinal fluid, Hydrocephalus, porencephalic cyst.

Corresponding Author: Dr Zafar Sultana, Associate professor of Anatomy, DCMS, Hyderabad, Telangana, India. **E-Mail:** drszafarm@gmail.com

Access this Article online	Journal Information
Quick Response code  DOI: 10.16965/ijar.2020.152	International Journal of Anatomy and Research RG Journal Impact: 0.21* ISSN (E) 2321-4287 ISSN (P) 2321-8967 https://www.ijmhr.org/ijar.htm DOI-Prefix: https://dx.doi.org/10.16965/ijar 
	Article Information
	Received: 25 Mar 2020 Peer Review: 25 Mar 2020 Revised: None
	Accepted: 20 Apr 2020 Published (O): 10 Aug 2020 Published (P): 10 Aug 2020

INTRODUCTION

Hydranencephaly (HE) is a rare, isolated abnormality occurring in less than 1 per 10,000 births worldwide [1]. The word HE is a fusion of hydrocephalus and anencephaly, but the condition actually represents a distinct disorder and is primarily a disease of the fetus, encephaloclastic encephalomalacia can occur in cases of severe perinatal insult [2]. HE occurs in less than 1 in 10,000 births and is characterized by near-total or total absence of the cerebral cortex and basal ganglia. The thalami, pons, cerebral peduncles, and cerebellum are usually

present, as may be a small amount of tissue from the occipital, frontal, and temporal lobes [3]. There is no known sex or racial predilection [4].

The exact etiology of HE is unclear. The most common etiological mechanism is intra uterine infarction of cerebral structures which is primarily due to the occlusion of supra-clinoid part of internal carotid artery [5].

HE occurs after the brain and ventricles have fully formed usually in second trimester. The brain destruction is complete or almost complete in a bilateral internal carotid artery

distribution with the cerebral hemispheres replaced by fluid covered with leptomeninges and dura. The cerebellum, midbrain, thalami, basal ganglia, choroid plexus and portions of occipital lobe all fed by posterior circulation are typically preserved [1].

The term HE encompasses several conditions that result in the extensive replacement of brain by cerebrospinal fluid. The cause of HE may be failure of normal brain development or an intrauterine disorder that destroys the brain parenchyma. Progressive obstructive hydrocephalus may cause HE if left untreated. Excessive pressure within the lateral ventricles destroys the midline structures and reduces the cerebral mantle to a thin membrane [6].

Toxoplasmosis and viral infections may cause this abnormality [2]. Toxic exposures and cocaine abuse have been reported, and described in rare syndromes [6]. In monozygotic twin pregnancies, death of one twin in the second trimester may cause a vascular exchange to the living twin through the placental circulation, leading to HE in the surviving fetus [7].

In HE computed tomography (CT) scanning demonstrates an absence of most of the supratentorial structures, with preservation of the falx, thalami, and various amounts of the occipital lobes and basal ganglia (see the images below). Macrocrania or microcrania may be present, or the head circumference may be normal. Clinical presentation consists of a vegetative state with few reflexive functions like sucking, swallowing, crying and moving extremities, depending on the severity of condition. The prognosis is poor with usually fatal outcome during first year [7,8].

CASE REPORT

11 years old female child born of third degree consanguineous parentage, third in order of four with maternal age 28 years and paternal age 35 years at the time of conception. Her second sibling expired due to similar problem at around 9 months. Other two siblings are essentially normal.

Antenatal ultrasound at 22 weeks revealed microcephaly and suspicion of hydranencephaly was kept. There is no history suggestive of TORCH infection or radiation exposure or significant drug exposure or alcoholism in mother.

At 26 weeks obstetrician decided to deliver baby expecting extremely poor outcome after discussing with family. Mother delivered a 1.5 kg female baby. She was kept in local ICU for one week for preterm care and discharged in stable condition.

On examination she is dysmorphic with microcephaly head circumference of 35cm (expected 53cm). She is wasted and stunted with weight of 9kg (expected 28kg) with global developmental delay (no neck control, no speech, visual and hearing impairments)

She has spastic quadriplegia with multiple adynamic contractures, feeding issues and drug resistant polymorphic seizures (epileptic encephalopathy).

Her CT brain & MRI brain showed HE (Fig.1 & 2)

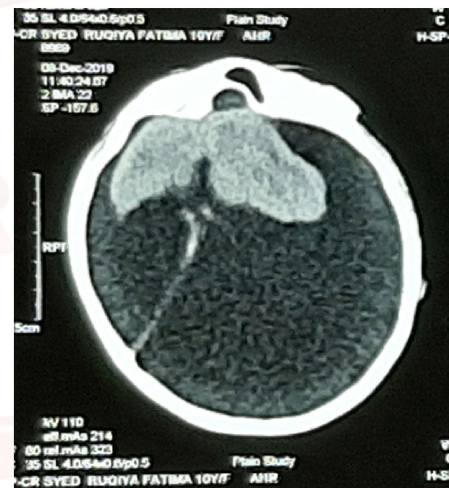


Fig. 1: Non contrast C T Brain : no anterior circulation cerebral cortex identified. Parts of posterior circulation such as part of frontal, temporal and occipital lobe preserved. The falx cerebri is present.

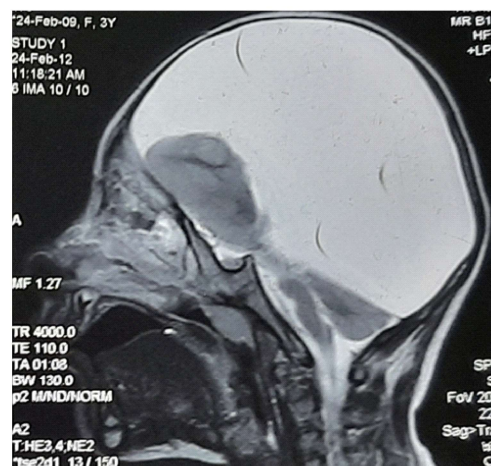


Fig. 2: MRI Brain plain study (sagittal section) revealed near absence of both cerebral hemispheres. The supratentorial space occupied by CSF. The posterior fossa contents and thalami are intact. The falx-cerebri is present.

DISCUSSION

In utero, HE is frequently diagnosed with ultrasonography, postnatally, cranial ultrasonography can detect the absence of cerebral tissue. However, MRI is probably the best modality for the overall evaluation of the anomaly and for the documentation of cortical remnants[9,10].

On prenatal ultrasound, an intact falx and a fluid-filled cranium can be seen. In newborns, macrocephaly and calvarial transillumination are present. The intact falx in HE differentiates it from alobar holoprosencephaly[11,12].

Knowledge about possible etiologies of HE comes from various observations and experiments. Studies in sheep and monkeys have demonstrated that bilateral ligation of the carotid arteries results in destruction of the cerebral hemispheres, with relative preservation of the portions of the brain supplied by the posterior circulation, giving an appearance similar to that of HE [13]. Because cerebrospinal fluid (CSF) diversion can successfully treat children with hydrocephalus, the distinction between HE and hydrocephalus is critical [14]. This distinction is also important in prognostic terms, as well as in connection with family support. However, differentiating HE from hydrocephalus and alobar holoprosencephaly in the prenatal period can be challenging; in difficult cases, prenatal magnetic resonance imaging (MRI) can be used to establish the correct diagnosis[15].

On prenatal ultrasound, an intact falx and a fluid-filled cranium can be seen. In newborns, macrocephaly and calvarial transillumination are present. The intact falx in HE differentiates it from alobar holoprosencephaly[16,17].

Head circumference at birth is large when HE is caused by obstructive frontal hydrocephalus and small when the condition is caused by intrauterine diseases. It may be large or small with primary malformations. HE and porencephaly are congenital cavitory anomalies of the brain resulting from failure of cell growth or necrosis. In HE, loss of the neuroepithelial cells reduces the thickness of the cerebrum to a thin layer of glial and meningeal cells[8]. As a result, CSF fills the defect because the defect is contiguous with

the lateral ventricles but not completely lined by ependyma.

It is thought to be arising from vascular insult involving the internal carotid artery after development of brain and ventricles occurs, usually in 2nd trimester of pregnancy; therefore, posterior circulation is intact. This results in cortical destruction (most of the cerebral cortex is absent) and forms a large cerebrospinal fluid (CSF) space anteriorly involving the and temporal lobes and intact areas in the posterior circulation, namely preserved thalami [8]. The third ventricle is normal, and the falx is seen in the midline [18]. The fetal head circumference would be expected to be normal.

Transillumination is a useful diagnostic tool for diagnosis of HE, in absence of other possible neuroradiological examination. According to the neurological signs and physical examination of the head in antenatal and postnatal periods, MRI remains the best imaging modality. Electroencephalogram may be useful to confirm the presence and type of seizures, as it relates to their treatment. Angio-MRI is a useful imaging tool to find congenital anomalies of the cerebral vascular structures [18]. The differential diagnosis is severe hydrocephalus, bilateral schizencephaly, and holoprosencephaly [20,21].

The etiopathogenesis of HE is still unknown, however most researchers support the hypothesis that the brain damage in HE is related to early internal carotid artery involvement, as demonstrated by a) angiographic and autptic observation, in which internal carotid artery anomalies, both aplastic and hypoplastic, are reported and b) by the anatomic distribution of the anomaly in HE, which follows the internal carotid artery supply [22,23,24] Thus, HE is categorized as a member of a group of circulatory developmental encephalopathies. Two main hypotheses have been advanced to explain the severe brain impairment. One is the destructive theory, for which the HE occurs after the brain and ventricles have partially or fully formed, and are then destroyed in utero, due to an encephaloclastic process. The anomalous event would occur after neural migration and before synaptogenesis, probably during the second trimester. It is during this phase that the fetal cerebral hemispheres present a relevant

transformation, with wide proliferation, which will generate the diencephalon, mesencephalon and the entire brainstem. The second hypothesis refers to a dysontogenetic process with an early disruption of organogenesis. These hypotheses cannot be confirmed, since there are no examples of HE in which the brain previously appeared normal at an MRI or ultrasound examination and was then destroyed [22,23,24].

The prognosis of HE is usually quite poor, Affected patients mostly die in utero. In the survivors, death usually occurs in the first year of life. Developmental delay, drug-resistant seizures, spastic diplegia, severe growth failure and respiratory infections are features which burden the life of these patients and are frequent causes of their death. However patients with survival of 20 [25], 22 [26] and 32 [27] years have been reported in the literature. The survival of the patient is related to the integrity of the brainstem, which regulates vital aspects, such as temperature, blood pressure, and cardiorespiratory function [27].

CONCLUSION

HE is an isolated rare congenital brain anomaly in which the greater parts of the cerebral hemispheres are replaced by cerebrospinal fluid (CSF). Bilateral occlusion of the internal carotid arteries mostly in the supraclinoid level in utero is a potential etiology. Ultrasound is the modality of choice for the diagnosis of HE in pre and postnatal period. HE is a rare disease with in-utero death as the most typical result and a very poor life expectancy. Diagnosis of HE does introduce some ethical problems. The importance of a timely diagnosis of HE cannot be ignored, as it may help the family to overcome emotional issues.

ABBREVIATIONS

HE-Hydranencephaly

Conflicts of Interests: None

REFERENCES

- [1]. Kurtz AB, Johnson PT. Diagnosis please case 7: HE. *Radiology*. 1999;210:419-22. <https://doi.org/10.1148/radiology.210.2.r99fe50419> PMID:10207424
- [2]. Deshmukh CT, Nadkarni UB, Nair K, et al. HE/ multicystic encephalomalacia: association with congenital rubella infection. *Indian Pediatr*. 1993 Feb. 30(2):253-7.
- [3]. Halsey JH Jr. HE. Vinken P, Bruyn G, Klawans H, eds. *Handbook of Clinical Neurology*. New York, NY: Elsevier; 1987;337-53.
- [4]. Cecchetto G, Milanese L, Giordano R, Viero A, Suma V, Manara R. Looking at the missing brain: HE case series and literature review. *Pediatr Neurol*. 2013 Feb. 48 (2):152-8. <https://doi.org/10.1016/j.pediatrneurol.2012.10.009> PMID:23337012
- [5]. Dublin AB, French BN. Diagnostic image evaluation of HE and pictorially similar entities, with emphasis on CT. *Radiology*. 1980;137:81-91. <https://doi.org/10.1148/radiology.137.1.7422865> PMID:7422865
- [6]. Pavone P, Praticò AD, Vitaliti G, Ruggieri M, et al. HE: cerebral spinal fluid instead of cerebral mantles. *Ital J Pediatr*. 2014;40:79. <https://doi.org/10.1186/s13052-014-0079-1> PMID:25326191 PMCID:PMC4421920
- [7]. Pant S, Kaur G, De JK. HE. *Kathmandu Univ Med J [KUMJ]* 2010;8:6.83-6. <https://doi.org/10.3126/kumj.v8i1.3227> PMID:21209513
- [8]. Kelly TG, Sharif UM, Southern JF, et al. An unusual case of HE presenting with an anterior midline cyst, a posterior calcified mass, cerebellar hypoplasia and occlusion of the posterior cerebral arteries. *Pediatr Radiol* 2011;41:274-7. <https://doi.org/10.1007/s00247-010-1894-1> PMID:21104240
- [9]. Poe LB, Coleman L. MR of HE. *AJNR Am J Neuroradiol*. 1989 Sep-Oct. 10(5 Suppl):S61.
- [10]. Poe LB, Coleman LL, Mahmud F. Congenital central nervous system anomalies. *Radiographics*. 1989 Sep. 9(5):801-26. <https://doi.org/10.1148/radiographics.9.5.2678293> PMID:2678293
- [11]. Poretti A, Boltshauser E, Huisman TA. Congenital brain abnormalities: an update on malformations of cortical development and infratentorial malformations. *Semin Neurol*. 2014;34 (3):239-48. <https://doi.org/10.1055/s-0034-1386762> PMID:25192502
- [12]. Kontzialis M., Choudhri A.F., Huisman T.A.G.M. (2019) Brain Developmental Malformations. In: Barkhof F., Jäger H., Thurnher M., Rovira À. (eds) *Clinical Neuroradiology*. Springer, Cham. https://doi.org/10.1007/978-3-319-68536-6_29
- [13]. Wintour EM, Lewitt M, McFarlane A, et al. Experimental HE in the ovine fetus. *Acta Neuropathol (Berl)*. 1996;91(5):537-44. <https://doi.org/10.1007/s004010050463> PMID:8740236
- [14]. Malheiros JA, Trivelato FP, Oliveira MM, Gusmão S, Cochrane DD, Steinbok P. Endoscopic choroid plexus cauterization versus ventriculoperitoneal shunt for HE and near HE: a prospective study. *Neurosurgery*. 2010 Mar;66(3):459-64. <https://doi.org/10.1227/01.NEU.0000365264.99133.CA> PMID:20173541
- [15]. Werner H, Gasparetto TD, Daltro P, Leandro Gasparetto E, Araujo Júnior E. Typical lesions in the fetal nervous system: correlations between fetal magnetic resonance imaging and obstetric ultrasonography findings. *Ultrasonography*. 2017 Oct 21. <https://doi.org/10.14366/usg.17040> PMID:29325241 PMCID:PMC6044224

- [16]. Poretti A, Boltshauser E, Huisman TA. Congenital brain abnormalities: an update on malformations of cortical development and infratentorial malformations. *Semin Neurol.* 2014 Jul. 34 (3):239-48. <https://doi.org/10.1055/s-0034-1386762> PMID:25192502
- [17]. Kontzialis M, Choudhri AF, Huisman TAGM. *Imaging Appearances.* Barkhof et al. *Brain Developmental Malformations.* Switzerland: Springer Nature Switzerland AG; 2019. https://doi.org/10.1007/978-3-319-68536-6_29
- [18]. Khalid M, Khalid S, Zaheer S, Redhu N, et al. HE: A rare cause of an enlarging head size in an infant. *N Am J Med Sci.* 2012;4(10):520-522. <https://doi.org/10.4103/1947-2714.102015> PMID:23112982 PMCid:PMC3482792
- [19]. Deshmukh CT, Nadkarni UB, Nair K, et al. HE/multicystic encephalomalacia: association with congenital rubella infection. *Indian Pediatr.* 1993 Feb. 30(2):253-7.
- [20]. Halsey JH Jr. HE. Vinken P, Bruyn G, Klawans H, eds. *Handbook of Clinical Neurology.* New York, NY: Elsevier; 1987;337-53.
- [21]. Greene MF, Benacerraf B, Crawford JM. HE: US appearance during in utero evolution. *Radiology.* 1985 Sep;156(3):779-80. <https://doi.org/10.1148/radiology.156.3.4023242> PMID:4023242
- [22]. Kim MS, Jeanty P, Turner C, et al. Three-dimensional sonographic evaluations of embryonic brain development. *J Ultrasound Med.* 2008 Jan;27(1):119-24. <https://doi.org/10.7863/jum.2008.27.1.119> PMID:18096737
- [23]. Lin YS, Chang FM, Liu CH. Antenatal detection of HE at 12 weeks, menstrual age. *J Clin Ultrasound.* 1992 Jan;20(1):62-4. <https://doi.org/10.1002/jcu.1870200112> PMID:1309546
- [24]. Covington C, Taylor H, Gill C, Padaliya B, Newman W, Smart JR, Charles PD: Prolonged survival in hydranencephaly: a case report. *Tenn Med.* 2003;96:423-424.
- [25]. Bae JS, Jang MU, Park SS: Prolonged survival to adulthood of an individual with hydranencephaly. *Clin Neurol Neurosurg.* 2008, 110: 307-309. <https://doi.org/10.1016/j.clineuro.2007.12.003> PMID:18222607
- [26]. Cecchetto G, Milanese L, Giordano R, Viero A, Suma V, Manara R: Looking at the missing brain: hydranencephaly case series and literature review. *Pediatr Neurol.* 2013;48:152-158. <https://doi.org/10.1016/j.pediatrneurol.2012.10.009> PMID:23337012
- [27]. McAbee GN, Chan A, Erde EL: Prolonged survival with hydranencephaly: report of two patients and literature review. *Pediatr Neurol.* 2000;23:80-84. [https://doi.org/10.1016/S0887-8994\(00\)00154-5](https://doi.org/10.1016/S0887-8994(00)00154-5)

How to cite this article:

Zafar sultana, Anantha kumari, Habib G Pathan. A RARE CASE OF HYDRANENCEPHALY: A CASE REPORT. *Int J Anat Res* 2020;8(3.2):7644-7648. DOI: 10.16965/ijar.2020.152